

Patten D. [Using ultrasound to teach anatomy in the undergraduate medical curriculum: an evaluation of the experiences of tutors and medical students.](#)  
*Ultrasound* 2015, 23(1), 18-28.

**Copyright:**

© D. Patten 2014.

**DOI link to article:**

<http://dx.doi.org/10.1177/1742271X14542173>

**Date deposited:**

29/05/2015

Insert deposit date.



This work is licensed under a [Creative Commons Attribution-NonCommercial 3.0 Unported License](#)

**Using ultrasound to teach anatomy in the undergraduate medical curriculum: an evaluation of the experiences of tutors and medical students.**

Dr Debra Patten

(Medical Sciences Education Development), Newcastle University, UK

**Corresponding Author**

Debra Patten, Medical Sciences Education Development, Newcastle University, Framlington Place, Newcastle, NE2 4HH, UK

Email: [debra.patten@ncl.ac.uk](mailto:debra.patten@ncl.ac.uk)

**Running Head:** Ultrasound to teach anatomy: staff and student experiences

**Abstract (250 words):** intro, methods, results, conclusions

This paper describes the experiences of staff and students at two U.K. medical schools, who introduced portable ultrasound (PU) as an imaging technology, to deliver clinical anatomy teaching and to aid skill development in interpretation of cross-sectional anatomy (CSA). A sonographer contributed to curriculum design and teaching, but mostly anatomy tutors delivered the teaching. This case study method evaluates staff and student perspectives on the ultrasound-based anatomy teaching. Quantitative data and qualitative data were collected and analysed.

Staff were positive about the experience. They described their expectations for students and solutions for practical issues regarding the teaching, but were concerned about their competency in scanning and wanted bespoke training for sonoanatomy teaching. Curriculum development was accelerated through engagement with a sonographer and an ultrasound champion. Students were extremely positive about their experience; they valued the expertise of a sonographer who taught more challenging sonoanatomy, but were equally positive regarding teaching sessions led by well-trained anatomy tutors who taught more simple sonoanatomy. Students affirmed most tutors expectations that ultrasound could reinforce existing anatomical knowledge, added clinical contextualisation, but not that US assisted in interpreting CSA. Students valued the introduction to the technology and found sonoimage interpretation challenging, but not insurmountable. Students wanted more instruction on ultrasound physics, an expansion of ultrasound curriculum, with smaller groups and opportunities to scan volunteers. These data support the case for the use of PU to deliver anatomy teaching and to prime medical students for later clinical encounters with PU.

**Abbreviated short Title:** Ultrasound to teach anatomy in undergraduate medicine: staff and student experiences.

**Keywords**

Portable ultrasound, undergraduate curriculum, medical students, anatomy, sonoanatomy

**Running head**

Using ultrasound to deliver undergraduate anatomy teaching.

**Short title.**

Staff and student perspectives on undergraduate anatomy teaching using portable ultrasound.

## Introduction

In the last decade the study of *living anatomy* has gained popularity in medical curricula. Living anatomy can be taught using portable ultrasound (PU)<sup>1-4</sup> which enables students to observe blood flow, how structures move with respiration, to appreciate normal anatomical variation, the depth of structures below the skin and to consider the inter-related anatomy of the whole organism. Moreover, PU permits anatomy to be studied in a clinical context using an imaging device which is commonplace in clinical practice. Use of ultrasound (US) as a learning tool may simultaneously reinforce existing anatomical knowledge and allow students to develop skills in interpreting two-dimensional US images; these skills may be transferable to other clinical imaging modalities<sup>1</sup>.

PU is increasingly used across the medical specialities and it is anticipated that eventually medical students will access PU early in clinical practice. Anatomists have anticipated this training need and in the last decade a few universities have responded to the increased application and use of Point of Care Ultrasound (PoCUS) by developing full, integrated vertical US curricula<sup>5-7</sup>. These curricula were developed with support from US manufacturers who freely supplied PU to the medical schools. Such generous arrangements have not been described in UK universities; this most likely explains the delay in US curriculum development here.

Demonstrations of US scanning have been used to teach living anatomy with reported success in terms of student satisfaction and anatomical knowledge gained/understood<sup>2, 8-11</sup>. Only Finn et al., (2012)<sup>3</sup> and Griksaitis et al., (2012)<sup>4</sup> comment on the efficacy of US in anatomy teaching noting that US is as efficacious as cadaveric teaching. Sweetman et al., (2013)<sup>12</sup> offer the most detailed insight into the students' experience of US commenting on specifics such as: improved visual understanding of anatomy, appreciation of anatomical variation, surface anatomy, effect of respiration of organ position, blood flow, clinical contextualisation, US measurement tools, observation of multiple views of organs, probe orientation, small group teaching, US physics, image interpretation and students' desire to scan volunteers themselves. To date, no studies have been found describing the tutor experience.

This paper describes the experiences of staff and students at two U.K. partner medical schools who introduced PU into anatomy teaching. The author has previously commented on the rationale for using PU in undergraduate anatomy teaching, as well as the ethical and practical issues to be considered in designing and delivering US-based teaching activities<sup>1</sup>. It is anticipated that other medical schools considering the use of PU as a tool to teach living anatomy will benefit from the findings presented here.

In 2005, both medical schools received two sets of Sonosite Micromaxx Portable US equipment from the<sup>†</sup>CETL4HealthNE in order to: introduce students to US equipment, demonstrate

---

<sup>†</sup> The CETL4HealthNE is a collaboration of four universities and NHS partners across the north-East of England. Its aim was to help prepare future health professionals better in order to meet the needs of a modernised NHS and the growing and changing expectations of its patients. CETL4HealthNE funded the purchase of portable ultrasound and the evaluation of the introduction of ultrasound across a range of undergraduate healthcare curricula.

living anatomy in a clinical context and enable skill development in sonogram interpretation (but not equipment controls or scanning technique). Instructors were anatomy tutors with no formal training in US scanning although a sonographer delivered some of the sessions.

## **Study recruitment, ethics and consent**

Student volunteers for scanning were recruited prior to teaching sessions via email. The sampling strategy for the evaluation of learning activities (LAs) was a convenient one namely, all participating students and instructors at both universities. These were invited to participate via email which outlined the rationale for the project, highlighted that some teaching sessions would be observed (opt-out forms for students were provided) and included participant information sheets and consent forms. All participants were invited to discuss the study with the researchers to address any concerns. One to one interviews were requested with instructors. Students were invited to participate in focus groups (i.e. opportunistic sampling).

All activities (scanning volunteers and evaluation) were approved by the ethics committees at both Universities (EC1/2007/02 and EC2/2009/02). Individual consent forms were signed by all participants who were reassured that non-participation or withdrawal from the study at any point would not incur any negative consequences. Data collection was anonymous.

## **Methods**

A '*realistic approach to evaluation*'<sup>13</sup> of programmes was adopted to gather qualitative data from all participants via interviews, focus groups and teaching observations. A case study method was employed to evaluate staff and student perspectives on the effectiveness and impact of PU activities within the undergraduate anatomy curriculum in two medical school partners (MS-A and MS-B). Both medical schools A and B delivered the same standard five-year curriculum with annual intakes of approximately 107 and 250 students respectively. Anatomy tutors (two at MS-A and one at MS-B) were permanent staff; in addition MS-B employed four extra anatomy demonstrators per semester. Medical students received anatomy instruction during years one and two.

Quantitative data were collected via formal module evaluations. Descriptive statistics (mean  $\pm$  S.D.) and non-parametric Mann-Whitney U tests were used to compare non-paired data between cohorts of students (anonymised data collection methods prohibited pairing of data). Statistical analyses were performed using IBM SPSS Statistics 19 (IBM Corp, Armonk, NY).

Qualitative data collected included: documentation analysis (e.g. timetables, teaching plans) observations of teaching sessions (n=6, 2 at MS-A), conducting interviews with educators (n=6, 4 at MS-A) and student focus groups (n=6, only 1 at MS-B due to timetabling difficulties). Data was analysed in iterative cycles using '*Grounded Theory*'<sup>14</sup> by a team of independent researchers. This approach permits an understanding of participants' attitudes towards PU to be generated from the data. Researchers coded data themes independently and cross-checked codes frequently to ensure a uniform coding procedure<sup>15</sup>. Lastly, researchers conducted independent analytical coding to establish hierarchy and/or relationships between codes and, following negotiation, this hierarchy was mutually agreed.

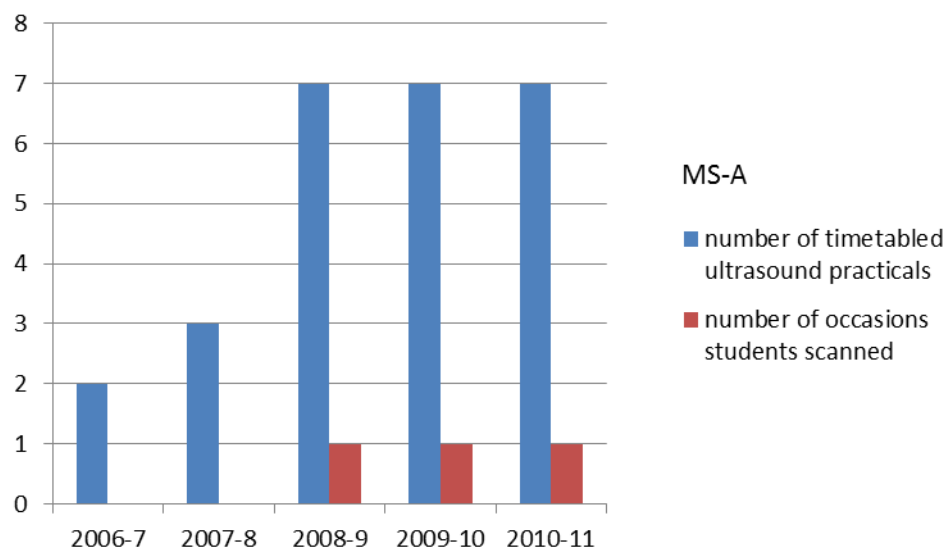
## Results

An analysis of course documentation from each medical school enabled the development of the US curriculum to be mapped over time and this is presented here, followed by formal module evaluation data. Finally, qualitative data from staff interviews, teaching observations and student focus groups are summarised and presented.

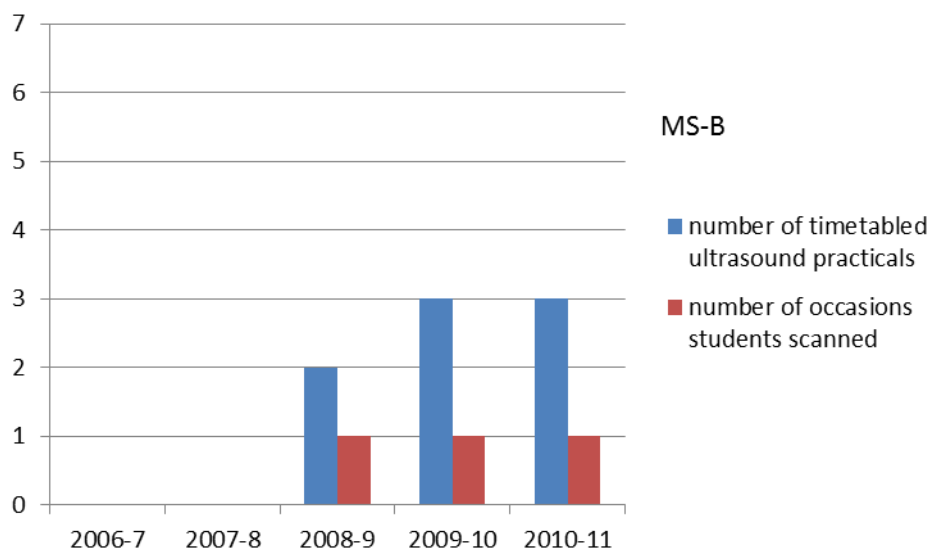
### Design and development of the ultrasound curriculum

The US curriculum was initially developed in MS-A then adopted by MS-B two years later. In MS-A (2006) suitable PU activities were identified and LA plans were designed following consultation with a sonographer; all LAs were piloted prior to introduction into the curriculum. Between 2006-8, a sonographer demonstrated PU to first and second year students. In 2008-9, anatomy tutors delivered PU demonstrations/activities to second year students. At MS-B there was no access to a sonographer and anatomy tutors delivered all PU sessions. In both medical schools the US curriculum developed to a steady state over a three to four year period with a gradual increase in the number of timetabled sessions and body regions covered.

Figures 1 & 2 illustrate the development of the US curriculum in both medical schools. MS-A made more rapid progress with five body regions being scanned in a variety of sessions (Table 1) over two academic cycles, compare to three regions for MS-B (Table 2). MS-A also used US regularly to demonstrate cardiovascular physiology in two physiology practical classes. Both medical schools incorporated PU into their widening access activities. Tables 1 and 2 highlight the typical features of US sessions in a given academic year (2008-9) in both medical schools, respectively. In all sessions, tutors projected the US image onto a large plasma screen. Group sizes and staff: student ratios were initially similar (1:20-25). From 2008-9 students were given the opportunity to scan each other and in these instances the ratios were 1:9 and 1:12 in MS-A and MS-B respectively.



**Figure 1:** Incidence of US activities in years 1 and 2 in MS-A over time



**Figure 2:** Incidence of US activities in years 1 and 2 in MS-B over time

Course /event	Cohort size	Group size	Year of study	Body region scanned	Tutor	Structures highlighted	Students scanning each other
5 year	102	22	1	Thorax	Sonographer x 1	4-chambered view of the heart; great vessels	no
	102	22	1	Abdomen	Sonographer x 1	Liver, gallbladder, spleen, kidneys, bladder, uterus, abdominal aorta	no
	93	24	2	Lower limb	Anatomist x 1	Femoral and popliteal vessels, quadriceps' and Achilles' tendons, patella ligament, great saphenous vein, sciatic & tibial nerves	no
	93	24	2	Upper limb	Anatomist x 1	Brachial artery, radial and ulnar arteries, carpal tunnel & flexor tendons, median nerve	no
	93	24	2	Neck	Anatomist x 3	Neck vasculature (common carotid artery and its bifurcation, internal jugular vein), thyroid gland, roots of the brachial plexus	<b>yes</b>
	102	53	1	Physiology practical	Physiologist	*Demonstration of principles of blood pressure measurement	no

						using US to illustrate visual occlusion of brachial artery and absence of blood flow sounds.	
	102	53	1	Physiology practical	Physiologist	Demonstration of the physiological cardiovascular response during simulated haemorrhage in a volunteer.	no
Widening access event						As above *	

**Table 1:** Features of US sessions in MS-A (2008/9)

Course /event	Cohort size	Group size	Year of study	Body region scanned	Tutor	Structures highlighted	Students scanning each other
5 year 4 year	211 30	20-25 30	Year 2 Year 1	Upper limb	Anatomist x 1	**Humerus, radius, ulna, carpal bones, brachial artery, radial and ulnar arteries, carpal tunnel & flexor tendons, median nerve	yes
5 year 4 year	211 30	20-25 25	Year 2 Year 1	Lower limb	Anatomist x 1	Femur, tibia, fibula, thigh muscles, quadriceps tendon, femoral and popliteal vessels, great saphenous vein, patella ligament, menisci, sciatic & tibial nerves	no
Widening access event	~30	8-10	Year 13 school children	Abdomen	Anatomist x 1	Liver and gall bladder	no
Widening access event	~30	~30	Year 13 school children	Carpal tunnel	Anatomist x 1	As above**	no

**Table 2:** Features of US sessions in MS-B (2008/9)



## Quantitative student evaluation data

Formal post-module evaluation data was collected by both medical schools (MS-A, Tables 3-4; MS-B's evaluation data has been published<sup>9</sup> and will be discussed later). Anatomists delivered US teaching in both medical schools, but in MS-A a sonographer delivered the more challenging US teaching sessions (abdomen/thorax). Year 1 students (Table 3) were overwhelmingly positive about their experience of US. There was a moderate increase (between 1-5%) in most of the scores in 2008-9. The largest changes in scores were a 15% decrease in agreement that it was difficult to interpret US images ( $p = 0.267$ ) and a 15% increase in agreement that US increased students' confidence in surface anatomy ( $p=0.008$ ). The percentage of students expressing a desire to use the equipment themselves remained high (92-3%) over the two year period.

<b>MS-A Year 1 Student Module Evaluation: 2007-8 and 2008-9</b> <b>Abdominal anatomy:</b> 30 minute demonstration	Mildly agree, agree, strongly agree (%)*		Mean score		P value ***
	2007-8 (n=79)	2008-9 (n=88)	2007-8 (n=79)	2008-9 (n=88)	
Tutor (S= sonographer, A=anatomist)	S	S	S	S	
Staff : student ratio	1:23	1:22			
Percentage response rate	84.9%	86.3%	84.9%	86.3%	
<b>The US stations help me to see anatomy within a clinical context.</b>	92	94	4.56±0.96	5.0±0.86	<b>0.002</b>
I found it difficult to interpret the images from the US station myself.	90	85	4.54±0.99	4.68±1.26	0.210
I can recognise anatomical structures in US images, once they have been pointed out to me by a demonstrator	92	91	4.67±0.92	4.82±0.94	0.182
The US station helps to reinforce my knowledge of the anatomical structures I have seen in other anatomical resources (prosections, models, cross-sectional images, etc.).	87	90	4.34±0.95	4.71±0.90	0.11
<b>The US station increased my confidence in surface anatomy by confirming the presence of the underlying structures</b>	70	85	4±1.03	4.43±1.01	<b>0.006</b>
The US station provided information that I haven't found from other sources.	72	-	3.94±1.06	-	
**I would like the opportunity to scan a volunteer myself using the PU equipment.	92	93			

**Table 3: Year 1 student evaluation data collected across 2 cohorts in MS-A**

Six-point Likert scale: 1=strongly disagree, 6 = strongly agree; \*combined percentages for 'strongly agree, agree and mildly agree' except for \*\* which was a yes/no question; - indicates missing data.

\*\*\* Mann Whitney U test at exact 2-tailed significance and  $p < 0.05$  in bold.

Year 2 students (Table 4) were also overwhelming positive about their experience of US. In 2008-9, all the sessions were delivered by anatomy tutors with a relative low staff-student ratio of 1:9. There were small, but statistically significant increases (between 1-6%) in most of the scores in 2008-9 (adding clinical contextualisation,  $p=0.000$ ; reinforces existing anatomical knowledge,  $p=0.004$ ). The largest change in scores was a 9% decrease in agreement that it was difficult to interpret US images ( $p=0.55$ ) and a 13% increase in agreement that US increased students' confidence in surface anatomy ( $p=0.00$ ). 84% of year 2 students in 2007 expressed a desire to use the equipment themselves. In 2008, students were given the opportunity to use the equipment under close-supervision and over an extended time period; 99% strongly agreed, agreed or mildly agreed that this was a useful experience.

<b>MS-A Year 2 Student Module Evaluation: 2007-8 and 2008-9</b>	Mildly agree, agree, strongly agree (%)*		Mean score		P value ***
	2007-8 (n=93)	2008-9 (n=78)	2007-8 (n=93)	2008-9 (n=78)	
<b>Upper limb anatomy:</b> 15 minute demonstration					
<b>Lower limb anatomy:</b> 15 minute demonstration					
<b>Neck anatomy:</b> 30 minutes demonstration (2007-8)					
<b>Neck anatomy:</b> 20 minutes demonstration + 40 minutes scanning (2008-9)					
Tutor (S= sonographer, A=anatomist)	S	A	S	A	
Staff : student ratio	1:28	1:9			
Total duration of 3 separate demonstrations (minutes)	60	90			
Percentage response rate	82.3%	83.4%	82.3%	83.4%	
<b>The US stations help me to see anatomy within a clinical context.</b>	89	96	4.61±1.16	5.24±0.84	<b>&lt;0.001</b>
<i>I found it difficult to interpret the images from the US station myself.</i>	71	60	3.96±1.13	3.83±1.35	0.551
I can recognise anatomical structures in US images, once they have been pointed out to me by a demonstrator	95	99	4.97±0.83	5.08±0.80	0.470
<b>The US station helps to reinforce my knowledge of the anatomical structures I have seen in other anatomical resources (prosections, models, cross-sectional images, etc.).</b>	94	96	4.65±0.87	5.03±0.79	<b>0.003</b>
<b><i>The US station increased my confidence in surface anatomy by confirming the presence of the underlying structures</i></b>	83	96	4.31±1.04	5.05±0.87	<b>0.000</b>
The US station provided information that I haven't found from other sources.	78	-	4.24±1.12	-	

**I would like the opportunity to scan a volunteer myself using the PU equipment.	84	-	-	-	
The opportunity to scan a volunteer myself using the PU equipment was useful	-	99	-	5.32±0.69	

**Table 4: Year 2 student evaluation data collected across 2 cohorts in MS-A**

Six-point Likert scale: 1=strongly disagree, 6 = strongly agree; \*, \*\* and \*\*\* as above.

MS-A 2007-8 cohort Year 1 (2007-8) and 2(2008-9) Student Module Evaluations compared	Mildly agree, agree, strongly agree (%)*		Mean score		P value ***
	2007-8 (n=79)	2008-9 (n=78)	2007-8 (n=79)	2008-9 (n=78)	
Tutor (S= sonographer, A=anatomist)	S	A	S	A	
Staff : student ratio	1:23	1:9	1:23	1:9	
Percentage response rate	84.9%	83.4%	84.9%	83.4%	
<b>The US stations help me to see anatomy within a clinical context.</b>	92	96	4.56±0.96	5.24±0.84	<b>0.000</b>
<b>I found it difficult to interpret the images from the US station myself.</b>	90	60	4.54±0.99	3.83±1.35	<b>0.000</b>
<b>I can recognise anatomical structures in US images, once they have been pointed out to me by a demonstrator</b>	92	99	4.67±0.92	5.08±0.80	<b>0.004</b>
<b>The US station helps to reinforce my knowledge of the anatomical structures I have seen in other anatomical resources (prosections, models, cross-sectional images, etc.).</b>	87	96	4.34±0.95	5.03±0.79	<b>0.000</b>
<b>The US station increased my confidence in surface anatomy by confirming the presence of the underlying structures</b>	70	96	4±1.03	5.05±0.87	<b>0.000</b>
The US station provided information that I haven't found from other sources.	72	-	3.94±1.06		
**I would like the opportunity to scan a volunteer myself using the PU equipment.	92	-			
The opportunity to scan a volunteer myself using the PU equipment was useful	-	99	-	5.32±0.69	

**Table 5: Comparison of 2 consecutive module evaluations collected from 1 cohorts in MS-A**

Six-point Likert scale: 1=strongly disagree, 6 = strongly agree; \*, \*\* and \*\*\* as above.

Table 5 shows feedback from one cohort over two years. A sonographer taught year 1 students in 2007-8, these proceeded to participate in year 2 ultrasound sessions in 2008-9 (anatomist-led sessions, with smaller groups, 1 session where students scanned). Comparison of the evaluation data

for these students showed statistically significant increases in agreement to statements regarding clinical contextualisation (4% increase ,  $p=0.000$ ), 'I find it difficult to interpret images myself' (30% decrease,  $p=0.000$ ), 'I can recognise structures once they have been pointed out' (7% increase ,  $p=0.004$ ), reinforcing existing anatomical knowledge (9% increase,  $p=0.000$ ) and increased confidence in surface anatomy (26% increase,  $p=0.000$ ) when the students were taught by an anatomist, had hands-on experience of scanning and where group size was small (~9 students).

### **Qualitative data from staff and students**

Three main themes emerged from analysis of qualitative data; these are start-up issues and staff and student perceptions of the experience overall.

#### ***Start-up issues raised by staff***

##### ***Ultrasound equipment***

Anatomy tutors recognised the importance of introducing a safe imaging technology and valued its ability to demonstrate living anatomy, anatomical relationships and variations, physiological changes and aspects of clinical relevance. They commented positively on the portability of the equipment but negatively regarding the screen size; they overcame this limitation by projecting US images onto a large plasma screen.

Tutor-led demonstration was the most practical design of LA due to the limited availability of equipment. Tutors reported that access to more machines would enable further curriculum development (in teaching and assessment). Latterly tutors borrowed extra equipment from other universities and developed LAs for larger groups of students. Although this was time-consuming, it afforded students the opportunity to use PU equipment themselves.

##### ***Training and Competency Issues***

Anatomy tutors were non-experts in sonography and were anxious about their competency in demonstrating US scanning to students. Tutors voiced concerns regarding access to training and, during observations, showed varying degrees of familiarity with the equipment. Whilst generic training was provided to permanent anatomy tutors by the US manufacturers at the time of purchase, the absence of bespoke training for anatomy teaching slowed curriculum development. The anatomist at MS-B trained rotations of anatomy demonstrators who were employed for one semester only; demonstrators, whilst trained, lacked experience with PU. Variation in tutor expertise was noted during teaching observations and commented upon by MS-B students in focus groups.

Tutors at MS-A accelerated their progress by collaborating with a local sonographer who provided basic training and helped to design and deliver teaching. One tutor sought training from a consultant with scanning expertise, but mostly clinical workloads precluded effective engagement with sonographers/radiologists. Some tutors used web-based training resources; others reported that they were able to achieve their aims with the level of training they had received and with practice.

##### ***Features of the Learning Environment***

In both medical schools the setup period before US activities was often demanding for support staff. Tutors projected sonoimages onto large plasma screens, dimmed the lighting conditions and carefully arranged the elements of the US demonstration for optimum viewing. Most LAs were designed for groups of ~25 students. In all observations a small number of volunteer students participated in scanning activities, although there were two observed sessions where all students participated in scanning. When students scanned each other in MS-A the staff: student ratio was 1:9 and the session lasted one hour. During the equivalent session in MS-B the student groups were larger (typically 12, from session observation) and the session lasted 30 minutes.

There was mixed feedback from students regarding the suitability of the learning environment. Negative feedback largely pertained to group size. All students consistently stated a preference for smaller group sizes in US activities.

### ***Staff Experiences***

#### ***Developing the curriculum***

A champion (anatomy tutor) was responsible for leading US curriculum development. Champions were recognised as important loci of expertise and experience, but one line manager highlighted the negative aspects of this arrangement if the champion became unavailable.

Tutors designed LAs, in part, to introduce US as an imaging modality. They reported that PU enabled them to teach living anatomy within a clinical context and that it was particularly effective for studying vascular structures. In teaching observations most tutors made references to the clinical applications of US and focused their learning outcomes on highlighting anatomy and developing students' skills in sonogram interpretation, rather than explicitly teaching scanning technique or operation of the equipment. All tutors commenced US demonstrations by explaining image orientation; the importance of this is evidenced by the observation that tutors revisited explanations of image orientation during sessions either at the students' request, or on noticing students' difficulty in interpreting images.

Later in the study and in response to feedback from students, tutors designed a LA to enable all students to scan the neck region of a peer. This area was chosen to illustrate the anatomy pertinent to central venous catheterisation (a core competency for F2 junior doctors).

#### ***Tutor's Perception of the Student Experience***

Tutors commented that students recognised, appreciated and were motivated by the clinical contextualisation afforded by US. During most teaching observations students were quiet and highly engaged during US demonstrations; at times there were audible gasps from the students, especially when colour Doppler functions were demonstrated. Tutors reported that students were eager to use the equipment themselves.

Nonetheless, tutors also perceived that not all students enjoyed their introduction to PU which was an area of concern. Experienced tutors quickly observed that some students found sonogram interpretation extremely challenging. Careful attention to the design of the learning environment and clear/modified explanations of image orientation (revisited when necessary) were implemented to ensure that most students were able to achieve the learning outcomes of the session.

## **Student Experiences**

### ***Introduction to the Equipment and Added Clinical Contextualisation***

In focus groups MS-A students were more positive about their encounter with PU than MS-B students, commenting on the clinical contextualisation afforded by US. Both groups of students appreciated the opportunity to experience an imaging technique they would use in their future careers and requested more sessions. Students lamented the short duration and the infrequency of the US sessions; this was especially the case for MS-B students whose US sessions were shorter with larger group sizes. It was clear from the behaviour of MS-A students especially during teaching observations and in focus groups that they enjoyed their US experience and found it to be memorable. Students in MS-A greatly appreciated the skill of the sonographer. For MS-B students the perceived value of the experience depended upon the skills of the tutor; students who were facilitated by an expert tutor were enthusiastic and engaged, whilst those with an inexperienced tutor complained about the lack of guidance and focus to the session.

### ***US adding value to anatomical teaching***

Most students reported that US highlighted the anatomical relationships between structures, enabled anatomical differences between individuals and/or pathologies to be seen and demonstrated the dynamic nature of anatomy with real time images. There was mixed feedback regarding the reinforcement of knowledge of cross-sectional anatomy; some felt US helped a little, others cited better resources for learning cross-sectional anatomy, no one said it helped greatly. The majority of students wanted US scanning and imagery embedded further into their curriculum.

### ***Students wanted opportunities to use the equipment themselves***

Most students wanted opportunities to operate the equipment and those who scanned, or were volunteer subjects, valued the experience highly. In MS-A students who scanned reported that the haptic experience of PU scanning aided their ability to interpret and remember the session and they requested more opportunities to scan. In one observation of students scanning it was noted that students gained confidence as the session proceeded since they began to explore the machine parameters and body structures outside of the prescribed learning outcomes. However, in observations of larger student groups in MS-B, it was noted that not all anatomy tutors facilitated scanning activities to a high standard; whilst these students still appreciated the opportunity to use equipment, in focus groups they complained about insufficient instruction and group size.

### ***Students found sonogram interpretation conceptually difficult***

Students frequently reported difficulty in interpreting sonograms; they found it difficult to recognise familiar anatomy when represented in grayscale, especially with a changing probe orientation. In some observations students asked for further explanations of image orientation and some, but not all, were subsequently able to grasp image interpretation. Experienced tutors were observed anticipating these difficulties and employing simple methods of clarifying orientation and highlighting anatomy to students whilst scanning. Students who scanned their peers reported that they found image orientation easier with practice.

### ***Introductory Physics and Machine Set-up***

Instruction on US image orientation and basic US physics was included in all observed US sessions. Nonetheless, all students interviewed requested more detailed explanations of US physics and knobology to facilitate their understanding of sonography.

## Discussion

Whilst there are evaluations of US activities in undergraduate medical curricula in the USA and Australia, there are presently no reports describing such an extensive integration and evaluation of US in undergraduate anatomy teaching in the U.K. Data are synthesised here to broadly examine the extent to which the tutors' aims for the students were met and the main issues which arose for staff and students. The tutors' aims were to: introduce PU as an imaging technology and as a tool to teach clinical anatomy and to facilitate skill development in interpretation of cross-sectional anatomy. Lastly, limitations of the study are considered.

### Introduction to PU as an imaging technology and a teaching tool

As others have reported<sup>2, 5, 9, 12, 16</sup> students welcomed the introduction of PU into anatomy teaching, valued opportunities to see and/or use an imaging modality which they anticipated using in the future<sup>6, 10, 17, 18</sup> and (indicative of their enjoyment and perceived value of the sessions) they wanted more frequent and longer US sessions<sup>2, 9-12, 19</sup>.

Overall MS-A students responded more positively than MS-B students. In an earlier study at MS-B, Swamy and Searle (2012), using 4-point Likert scales, reported that 63% (2008-9) and 78% (2009-10) of second year medical students found US teaching useful or essential, whereas 2 cohorts of second year MS-A students experiencing the same curriculum reported 83-96% agreement (Table 3) on the perceived benefits of US; year 1 MS-A students were similarly enthusiastic with equivalent scores ranging from 70-94% (Table 4). For example, MS-A students agreed that US reinforced anatomical knowledge, whether taught by a sonographer (87% & 90% for year 1 students, 94% year 2 students) or an anatomist (96%), whereas only 22% and 40% of year 2 MS-B students (taught by anatomists) agreed that *'US improved their understanding of anatomy quite a lot/considerably'*. It is unclear whether the disparity in scores here is due to the differing Likert scales or other factors which were highlighted in focus groups such as group size, staff: student ratio or varying experience of tutors. In addition only one focus group was conducted at MS-B, this data may not be representative of the entire cohort.

Other studies report that US reinforces anatomical knowledge<sup>2, 5, 10</sup> and also highlights anatomical variation<sup>11, 12</sup>, these observations were echoed by MS-A students in focus groups. Only MS-A students confirmed tutors' predictions that US added value to anatomy teaching through its ability to dynamically illustrate anatomical relationships and variation in real-time.

Similar to Sweetman et al., (2012) and Brown et al., (2012), MS-A students appreciated the skill of the sonographer with 72-78% of MS-A students taught by a sonographer agreed that US delivered a different learning experience compared to other teaching resources. Sweetman et al., (2012) also comment that sonographer-led teaching increased students' confidence in surface anatomy. MS-A students agreed with this statement regardless of the tutor's expertise (sonographer: 72% for year 1 students, 83% year 2 students and anatomists: 96% for year 2 students). MS-B did not comment on this in focus groups or questionnaires, perhaps reflecting that overall they were less positive about

their US experience for the reasons mentioned previously. However, neither this study nor Brown's (2012) investigated retention of this knowledge and /or confidence over time.

Similar to other reports<sup>9, 12, 20, 21</sup>, students in this study universally requested smaller groups. Patten et al., (2011) advise that students need to see the probe position on the volunteer and the resultant image in the same field of view, so that students can integrate information from all elements of the demonstration; in large groups it is likely that only students close to the demonstration can see all elements of it which may explain students desire for smaller groups.

As other studies confirm<sup>2, 9, 10</sup> students experienced difficulty in understanding image orientation. However, in MS-A as US teaching became more embedded, fewer students reported difficulty in interpreting sonograms. While tutors observed that some students would always struggle with image orientation, most students commented that with repeated explanations of image orientation and anatomy (i.e. a more didactic style of teaching), they could interpret sonograms. 90% and 85% of year 1 students over two cohorts agreed that they struggled to interpret sonograms themselves, but 92% and 91% agreed that they could do so once structures has been pointed out to them; these students were taught by a sonographer. Interestingly, fewer year 2 students (71% and 60%) agreed that they struggled to interpret sonograms themselves, with 95% and 99% reporting that they could do so after instruction; these students were taught by a sonographer in 2007-8 and anatomists in 2008-9, respectively. This perceived improvement over time may be due to several factors including: students' increased exposure to US (especially for year 2 students) and improved understanding of anatomy/sonoanatomy, improved instruction by anatomy tutors as they gained scanning skills and familiarity with the equipment, increased teaching time and improved staff: student ratios (e.g. for the 2007-8 cohort in year 2 where students reported most favourably, the ratio improved from 1:23 in year 1 to 1:9). Ivanusic et al., (2010) have reported the need to revisit image orientation during teaching, but Brown et al., (2012) report that only 26% of year 1 students experienced difficulty interpreting sonograms when taught didactically by experts and 98% could also identify vascular structures in sonograms when tested. Swamy and Searle (2012) found that cross-referencing between cross-sectional anatomy images and sonograms improved students' confidence in identifying bone, muscle, blood vessels, tendons and nerves. In this study students reported that tutor's using a sheet of paper to represent the ultrasound beam/plane aided their understanding of image orientation (Table 8). These data indicate that clear and regular didactic explanations of image orientation are critical for the success of US teaching and support the argument that, with training and practice, anatomists can deliver basic US teaching to a standard similar to an expert when the anatomy to be studied is simple (as highlighted in Tables 1-2).

As others have described<sup>12</sup>, students requested training in US physics and knobology to aid their understanding of the technology. This omission was deliberate since tutors were primarily focussing on anatomy and image interpretation. These data suggest that a fundamental grounding in US techniques may allow students to conceptualize image and probe orientation more easily.

There is debate in the literature regarding whether students should perform US scans. Reflecting their enthusiasm for the sessions, most MS-A students (84-99%) reported a desire to operate PU themselves. This was reaffirmed in focus groups where students commented that the haptic experience of scanning their peers aided image orientation and interpretation. Several pilot studies



<sup>19, 22-25</sup> and studies with student cohorts <sup>5, 7, 18, 26</sup> show that, with focussed training, students can gain sufficient scanning proficiency for clinical examination. However, Sweetman et al., (2013)<sup>12</sup> caution infrequent scanning opportunities encourages confidence without skill development, since ultrasound scanning did not improve students' performance in clinical examinations. Stringer et al, (2012)<sup>10</sup> agree and advocate large group didactic teaching by a sonographer. These data indicate students can operate PU to explore simple anatomy, but no further conclusions can be drawn since acquiring scanning proficiency was not an aim of this study.

### **Adding clinical context**

As others have reported <sup>2, 9, 10, 12</sup>, students at MS-A confirmed tutors' predictions that US added clinical contextualisation to anatomy teaching, and this was the case for MS-A students in sonographer-led (92 & 94% for year 1 students, 89% year 2 students) and anatomist-led (96%) sessions; MS-A students were effusive about this in focus groups but MS-B students did not discuss it. As previously discussed, MS-B's larger group sizes, variability in tutor expertise and insufficient focus group data may explain this disparity between student experiences.

### **Development of students' skills in cross-sectional interpretation**

Tutors anticipated that students would be able to develop skills in cross-sectional image interpretation by observing/using US and that these skills may be transferrable to other imaging modalities. However, development of general skills in cross-sectional image interpretation did not emerge as a strong theme from any focus group; students universally reported that without careful instruction from tutors they found sonogram interpretation conceptually difficult. Whilst they were able to recognise sonoanatomy when it was outlined to them during the teaching session, it seems that on reflection during focus groups, any perceived skill development in cross-sectional image interpretation was not a significant outcome of US teaching. It is likely that the amount and level of US teaching in the curricula was insufficient to facilitate such transferrable skill development.

### **Sustainability and barriers to curriculum development**

Anecdotally in the UK, sonographers are concerned that non-sonographers teaching medical students may use poor scanning technique or be unable to interpret sonograms. This perspective is a potential barrier towards the development of US curricula outside of the profession and may explain the difficulty some tutors experienced in trying to engage with local sonographers. In this study, the scope of US teaching was limited to the provision of an introduction to US and a demonstration of principles of US image interpretation; this enabled a sonographer to contribute without compromising their professional position.

Identification of a champion and engagement with a sonographer facilitated curriculum development for MS-A, but lack of appropriate training was a barrier for some tutors. This concern was justified since this study revealed varied expertise amongst anatomy tutors. US manufacturers provided only generic training whereas bespoke training was required. Although participants were able to sign up for specialist training courses at an additional expense, the cost and prescriptive nature of these courses was the prohibitive. If US suppliers offered individualised training and training resources for anatomy tutors at the time of purchase, this would help tutors to develop skills at an appropriate level and pace for their own curricula and to disseminate training to other tutors.

This study suggests that with appropriate training and practice, anatomy tutors can use and teach basic scanning where the anatomy to be highlighted is simple. However, further research is required to ascertain the effectiveness of this teaching regarding students' skills in sonogram acquisition and interpretation, scanning technique, knobology and ultrasound physics.

There are other examples of non-experts teaching sonographic anatomy to medical students<sup>27, 28</sup>, and this may be appropriate for sessions highlighting anatomy or to enhance clinical examination, but as Hoppmann et al., (2011)<sup>7</sup> and Rao et al., (2008)<sup>5</sup> describe, full US curriculum should be delivered by those with professional expertise and experience in ultrasonography. In the long term, engagement with the sonography profession and professional bodies such as BMUS may facilitate US curriculum development in the UK. Establishment of achievable learning aims and outcomes and demonstrations of competency in scanning by non-sonographers at dissemination events may ease the professional concerns voiced by sonographers.

### **Limitations**

In terms of limitations, this study does not investigate students' skills in image interpretation assessed pre- and –post intervention and the value of the early encounter with US is not evaluated to assess its impact in the clinical years when US is used, but these issues could be addressed in future studies. Also, additional focus groups in MS-B would have permitted a thorough exploration of the reasons why these sessions were perceived more negatively.

### **Conclusion**

The introduction of PU into anatomy teaching was successful with staff and students responding positively to the experience. With training and practice anatomy tutors can use ultrasound effectively to add clinical contextualisation to living anatomy teaching and to provide an early introduction to US when the anatomy to be highlighted is simple. Sonographers or other experts must be involved in curriculum design and delivery of some sessions and that PoCUS Clinical examination should be delivered by clinical experts. There is value in allowing undergraduate students to scan their peers; scanning allows students to participate in active learning, haptic feedback obtained during scanning aids image orientation and interpretation and the clinical experience<sup>‡</sup> fosters enthusiasm for the session. In the UK progress towards a vertically integrated US curriculum model is desirable, but access to equipment and expertise means that alternative models operates in UK.

### **ACKNOWLEDGEMENTS**

The author would like to acknowledge the contributions of Dr Claudia Morgavi and Dr Gabrielle Finn for data collection and analysis, Professor Pauline Pearson, Mrs Lesley Scott, Mrs Suzanne Powell and Dr Jason Scott, for their contributions to data analysis and feedback on the CETL4Health Ultrasound Evaluation Report<sup>29</sup>.

---

‡

## References

- 1 Patten D, Donnelly L, Richards S. Studying living anatomy: the use of portable ultrasound in the undergraduate medical curriculum. *International Journal of Clinical Skills*. 2010;4(2):72-7.
- 2 Ivanusic J, Cowie B, Barrington M. Undergraduate student perceptions of the use of ultrasonography in the study of "Living Anatomy". *Anat Sci Educ*. 2010;3(6):318-22.
- 3 Finn G, Sawdon M, Griksaitis M. The additive effect of teaching undergraduate cardiac anatomy using cadavers and ultrasound echocardiography. *Eur J Anat*. 2012;16:199-205.
- 4 Griksaitis MJ, Sawdon MA, Finn GM. Ultrasound and cadaveric prosections as methods for teaching cardiac anatomy: A comparative study. *Anatomical Sciences Education*. 2012;5(1):20-6.
- 5 Rao S, van Holsbeeck L, Musial JL, Parker A, Bouffard JA, Bridge P, et al. A Pilot Study of Comprehensive Ultrasound Education at the Wayne State University School of Medicine. *Journal of Ultrasound in Medicine*. 2008;27(5):745-9.
- 6 Afonso N, Amponda D, Yang J, Mendez J, Bridge P, Hays G, et al. Adding new tools to the black bag - introduction of ultrasound into the physical diagnosis course. *Journal of General Internal Medicine*. 2010;25(11):1248-52.
- 7 Hoppmann R, Rao V, Poston M, Howe D, Hunt P, Fowler S, et al. An integrated ultrasound curriculum (iUSC) for medical students: 4-year experience. *Crit Ultrasound Journal*. 2011;3:1-12.
- 8 Fernandez-Frackelton M, Peterson M, Lewis RJ, Perez JE, Coates WC. A bedside ultrasound curriculum for medical students: prospective evaluation of skill acquisition. *Teach Learn Med*. 2007;19(1):14-9.
- 9 Swamy M, Searle RF. Anatomy teaching with portable ultrasound to medical students. *BMC Med Educ*. 2012;12:99.
- 10 Stringer MD, Duncan LJ, Samalia L. Using real-time ultrasound to teach living anatomy: an alternative model for large classes. *N Z Med J*. 2012;125(1361):37-45.
- 11 Brown B, Adhikari S, Marx J, Lander L, Todd GL. Introduction of ultrasound into gross anatomy curriculum: perceptions of medical students. *J Emerg Med*. 2012;43(6):1098-102.
- 12 Sweetman G, Crawford G, Hird K, Fear M. The benefits and limitations of using ultrasound to supplement anatomical understanding. *Anatomical Sciences Education*. 2013;6(3):141-8.
- 13 Pawson R, Tilley N. *Realistic Evaluation*. London: Sage 1997.
- 14 Glaser BG, Strauss AL. *The Discovery of Grounded Theory*. : Piscataway, NJ: Aldine Transaction 2007.
- 15 Lingard L, Albert M, Levison W. Grounded theory, mixed methods, and action research. *BMJ*. 2008;337(39602):690162.47.
- 16 Teichgräber U, Meyer J, Poulsen Nautrup C, von Rautenfeld D. Ultrasound anatomy: a practical teaching system in human gross anatomy. *Med Educ*. 1996;30(4):296-8.
- 17 Gogalniceanu P, Sheena Y, Kashef E, Purkayastha S, Darzi A, Paraskeva P. Is basic emergency ultrasound training feasible as part of standard undergraduate medical education? *Journal of surgical education*. 2010;67(3):152-6.
- 18 Butter J, Grant T, Egan M, Kaye M, Wayne D, Carrion-Carire V, et al. Does ultrasound training boost Year 1 medical student competence and confidence when learning abdominal examination? *Medical Education*. 2007;41(9):843-8.
- 19 Wicke W, Brugger PC, Firbas W. Teaching ultrasound of the abdomen and the pelvic organs in the medicine curriculum in Vienna. *Medical Education*. 2003;37(5):476-.
- 20 Helio A, Hansen A, Holck P, Laerum F. Ultrasound 'electronic vivisection' in the teaching of human anatomy for medical students. *European Journal of Ultrasound*. 1997;5:203-7.

- 21 Teichgräber U, Meyer J, Berens von Rautenfeld D. Teaching applied anatomy to senior medical students with an emphasis on surgery and radiology. . *Surgical and Radiologic Anatomy*. 1996b;18(2):141-2.
- 22 Arger PH, Schultz S, Sehgal C, Cary TW, Aronchick J. Teaching medical students diagnostic sonography. *Journal of Ultrasound in Medicine* 2005;24(10):1365-9.
- 23 Shapiro RS, Ko PK, Jacobson S. A pilot project to study the use of ultrasonography for teaching physical examination to medical students. *Comput Biol Med*. 2002;32(6):403-9.
- 24 Wong I, Jayatilleke T, Kendall R, Atkinson P. Feasibility of a focused ultrasound training programme for medical undergraduate students. *Clinical Teacher*. 2011;8(1):3-7.
- 25 Barloon T, Brown B, Abu-Yousef M, Ferguson K, Schweiger G, Erkonen W, et al. Teaching physical examination of the adult liver with use of real-time sonography. *Acad Radiol*. 1998;5(2):101-3.
- 26 Wittich C, Montgomery S, Neben M, Palmer B, Callahan M, Seward J, et al. Teaching cardiovascular anatomy to medical students by using a handheld ultrasound device. *JAMA*. 2002;288(9):1062-3.
- 27 Celebi N, Zwirner K, Lischner U, Bauder M, Ditthard K, Schürger S, et al. Student Tutors Are Able to Teach Basic Sonographic Anatomy Effectively - a Prospective Randomized Controlled Trial. *Ultraschall in Med*. 2012;33(EFirst):141-5.
- 28 Knobe M, Münker R, Sellei RM, Holschen M, Mooij SC, Schmidt-Rohlfing B, et al. Peer teaching: a randomised controlled trial using student-teachers to teach musculoskeletal ultrasound. *Medical Education*. 2010;44(2):148-55.
- 29 Pearson P, Scott L. From Novel Concept to Valued Collaboration: CETL4HealthNE Final Evaluation (Full Report) University of Newcastle upon Tyne 2013.